www.nesa-india.org • E-mail: nesapublications@gmail.com
International Journal on Biological Sciences

International Journal on Biological Sciences 13 (1), January-June 2022, pp 80-82
ISSN No.: 0976-4518

CHROMIUM INDUCED NECROSIS IN KIDNEY AND LIVER OF *CHANNA PUNCTATA*

Mamta Pal

Department of Zoology
University of Lucknow (U.P.), India

Review Paper

Received: **28.04.2022** Revised: **10.05.2022** Accepted: **18.05.2022**

ABSTRACT

Long term exposure caused severe histopathological alterations in the hepato-renal tissue of the chromium exposed fish, *Channa punctata* indicating its toxic nature. It initially acts by changing the structural and/or functional properties of molecules essential for cellular activities. Eight set of the treated group having 96 hours LC 50 x1/10 concentration of chromium trioxide was run for 60 days. The histopathological changes were observed in the liver and kidney tissues with significant vacuolization and hyperplasia. After 60 days of the exposure period, necrosis and vacuolization were seen. Inflammation was observed to increase to a large extent.

Keywords: *Channa punctata*, Chromium, Liver, Kidney, Necrosis.

INTRODUCTION

A pollutant affects a biological system at many levels. The metal which has a relatively high density and toxic at low quantity is referred as 'heavy metal' (Kumar *et al.,* 2019). Anthropogenic activities continuously increase the amount of heavy metals in the environment, especially in aquatic ecosystem (Srivastava and Prakash, 2019). Metals contaminated water are adversely affecting the ecological balance and biodiversity of the recipient environment (Kaur and Mishra, 2019). It is released into the aquatic environment through both geogenic processes as well as anthropogenic activities such as metal smelting and chemical manufacturing (Prakash and Verma, 2020). Heavy metal in the aquatic environments has been as a potential threat to the aquatic organisms including fishes. Metals are known to inhibit the several biochemical and physiological mechanism vital for fish metabolism (Srivastava and Prakash, 2019). Chromium, one of the twenty three heavy metal toxicants, may be transported to aquatic ecosystems as a result of both natural (weathering and erosion) and anthropogenic (industrial and agricultural) activities (Kumar *et al*, 2019).

Histopathology is an indispensable and powerful technique in establishing routine toxicological studies performed for the purpose of risk assessment of living resources, useful in exposing the tissue contents and mechanisms of action at cellular level. To assess its usefulness in toxicology with shellfishes, several investigators have performed experiments using various environmental contaminants (Yasmeen, 2019).

It initially acts by changing the structural and/or functional properties of molecules essential for cellular activities. These molecular changes then affect the structure and function of organelles and cells, which alter the physiological state of the organization (Jagoe, 1996). Thus, the histopathological examination can indicate potential problems before the appearance of effects

*Corresponding author: *mamtapal832@gmail.com*

at higher organizational levels. In other words, structural changes in cells and tissues are excellent biomarkers of pollutants exposure, (Hinton *et al.,* 1992; Hinton, 1993) and they provide an early warning of pollution effects. Fishes held under adverse ecological conditions show endocrine imbalance, cellular hyperplasia and lymphoid involution (Brown *et al.,* 1978). Inflammatory response, necrosis and lesions are some of the important undesirable changes at the tissue level, gradually affecting the organ and then the organ system as a whole.

MATERIALS AND METHODS

Several sets of experiments were designed to generate the raw data for the determination of LC 50 after 96 hours exposure period. Fishes of almost the same length and weight were acclimatized to the laboratory conditions after hand netted from the river Gomti, Lucknow. Ten specimens of the fishes were taken for each concentration level of the chromium trioxide. 5μg/l water load was taken throughout the study. LC 50 was estimated to be 76.82 mg/l.

The test experiments were performed for an exposure period of 7, 15, 30 and 60 days and the concentration and water load were maintained the same throughout. Eight sets of experiments were set up. First, second, third and fourth sets were of control groups having no test chemical for 7, 15, 30 and 60 days of exposure period respectively. The Fifth set of the treated group having 96 hours LC 50 x1/10 concentration of chromium trioxide was run for 7 days, the sixth set of the treated group having 96 hours LC50 x1/10 concentration of Chromium trioxide was run for 15 days and the seventh set of the treated group having 96 hours LC50x 1/10 concentration of chromium trioxide was run for 30 days. The Eighth set of the treated group having 96 hours LC 50 x1/10 concentration of chromium trioxide was run for 60 days.

After the termination of each set of experiments, the test fishes were taken out of aquaria with utmost care and promptly anaesthetized with a wild dose of benzocaine. Kidney and liver were processed by fixation, dehydration and staining, followed by microscopic examination.

RESULTS AND DISCUSSION

Liver is responsible for digestion, filtration and storage of food energy in the form of glycogen. It is the vital organ for detoxification and biotransformation process of unwanted and toxic substances. Fish liver is susceptible to chemical damaged due to slow blood flow and lower rate of bile flow. As the liver has multiple metabolic functions, such damage can have serious effects on the metabolism (Srivastava and Prakash, 2019; Kaur and Mishra, 2019).

The liver of *Channa punctata* is a yellowish-brown gland that consists of two lobes, which are further, subdivided into lobules each made up of several polyhedral hepatocytes. Normally, these cells are systematically arranged and appear as the radiating spokes of a wheel. This arrangement led to the assigning of the name liver parenchyma to the groups of hepatic cells.

The normal histology of the liver of the control fish shows the typical parenchymatous appearance (Photo Image 1). The hepatic cells absorb food material from the blood sinusoids. The centre of this sequence of the polyhedral hepatic cells is always occupied by the central (interlobular) vein. The hepatocytes or lobules with columns of cells are separate–from each other by small blood spaces or sinusoids. Sinusoids are fewer in number and are internally lined by endothelial cells with very prominent nuclei.

Considerable alterations were observed in the histo anatomy (microtomy) of the liver of the fishes exposed to sublethal concentrations of chromium trioxide for different exposure periods. The common observations after all the exposure periods include reduction in the size of hepatocytes, narrowing of bile ducts and necrosis. These changes being common after all exposures periods, the degree of insults showed variation along the increasing exposure periods.

After the first 7 days of the exposure period, the hepatocytes showed minor inflammation. After 15 days of the exposure period, considerable inflammation along with mild pycknosis was observed. After 30 days of the exposure period, severe inflammation along with considerable necrosis and pycknosis were observed. Significant vacuolization and hyperplasia were also seen (Photo Image 1, 2). After 60 days of the exposure period, necrosis and vacuolization were seen. Inflammation was observed to increase to a large extent.

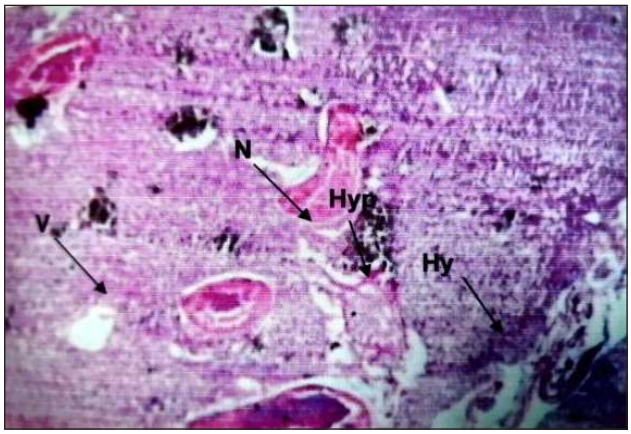

Photo Image 1: Section of liver of *C. punctata* exposed to LC_{50} 1/10 of CrO3 for 30 days showing necrosis (N), hypertrophy (Hy), Vacuolization (V) and hyperplasia (Hyp) of hepatocytes, (H & E x 100).

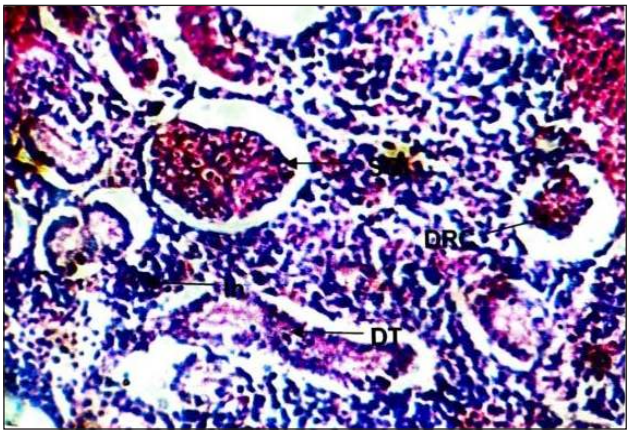

Photo Image 2: Section of the kidney of C. punctata exposed to LC_{50} 1/10 of CrO_3 for 30 days showing inflammation (In), Swelling in glomerulus (SGI), degenerating renal capsule (DRC) and distorted renal tubule (DT) of hepatocytes, (H & E x 100).

REFERENCES

1. **Brown V.M., Abram F.S.H. and Collins L.J.** (1978). The Acute Lethal Toxicity to Rainbow trout for LAS Surfactant and of its Degradation Products. *Tenside. Surfactants Deterg.,* 15(2): 57-59.
2. **Hinton D.E., Baumann P.C., Gardner G.P., Hawkins W.E., Hendricks J.D., Murchelano R. A. and Okihiro M.S.** (1992). Histopathological biomarkers. In: Biomarkers, Biochemical, Physiological, Histological markers of anthropogenic stress. Lewis Publishers. 55p.
3. **Hinton D.E.** (1993). Toxicological histopathological of fishes: A systematic approach and overview. In: Pathology of Marine And Estuarine organisms. Couch, J.A. and Journie, J.A. (eds.). CRC Press, Boca Raton, FL. pp.177-215.
4. **Jagoe C.H.** (1996). Responses at the tissue level: Quantitative methods in histopathology applied to ecotoxicology. Published by Lewis publishers, Boca Raton, New York, London, Tokyo.
5. **Kaur G. and Mishra B.K.P.** (2019). Histopathological changes in Liver of fish *Channa punctatus* exposed to sub lethal concentration of Hybrid Pesticide. *International Journal of Biological Innovations*. 1(2): 83-86. https://doi.org/10.46505/IJBI.2019.1209.
6. **Kumar A., Prakash S., Parmar A. and Bajpeyee A.K.** (2019). Effect of cadmium on fresh water teleost, *Heteropneustes fossilis* (Bloch). *International Journal of Biological Innovations.* 1 (1):14-17. https:// doi.org/ 10.46505/ IJBI. 2019. 1103.
7. **Prakash S. and Verma A.K.** (2020). Effect of Arsenic on Serum Biochemical parameters of a fresh water cat fish, *Mystus vittatus. International Journal of Biological Innovation*s. 2 (1): 11-19. https://doi.org/10.46505/IJBI.2020.2102.
8. **Srivatava N.K. and Prakash S.** (2019). Effect of Zinc on the Histopathology of Gill, Liver and Kidney of Fresh Water Catfish, *Clarias batrachus* (Linn.). *International Journal of Biological Innovations*. 1 (1): 8-13. https://doi.org/ 10.46505/IJBI.2019.1102.
9. **Yasmeen S.** (2019). Cadmium induced histopathological alterations in female gonad of freshwater bivalve mollusks, *Lamellidens marginalis* during summer season. *International Journal of Biological Innovations.* 1 (2):73-77. https://doi.org/10.46505/IJBI.2019.1207